

Telemedicine difficulties for Family Physicians in dermatological cases

Zeeshan Najam Khan

Correspondence:

Dr Zeeshan Najam Khan, MBBS, MRCGP, CCFP
Family Physician, Orleans Family Health Clinic
210 Centrum Blvd, Orléans, ON K1E3V7
Ottawa, Canada
Email: drkhanz@gmail.com

Received: September 2020; Accepted: October 2020; Published: November 1, 2020

Citation: Zeeshan Najam Khan. Telemedicine difficulties for Family Physicians in dermatological cases. World Family Medicine. 2020; 18(10): 109-115 DOI: 10.5742/MEWFM.2020.93899

Introduction

Whilst the general public panics about Covid-19, family physicians are facing difficulties in assessing skin-related cases, especially when dealing with patients concerned about undiagnosed skin conditions.

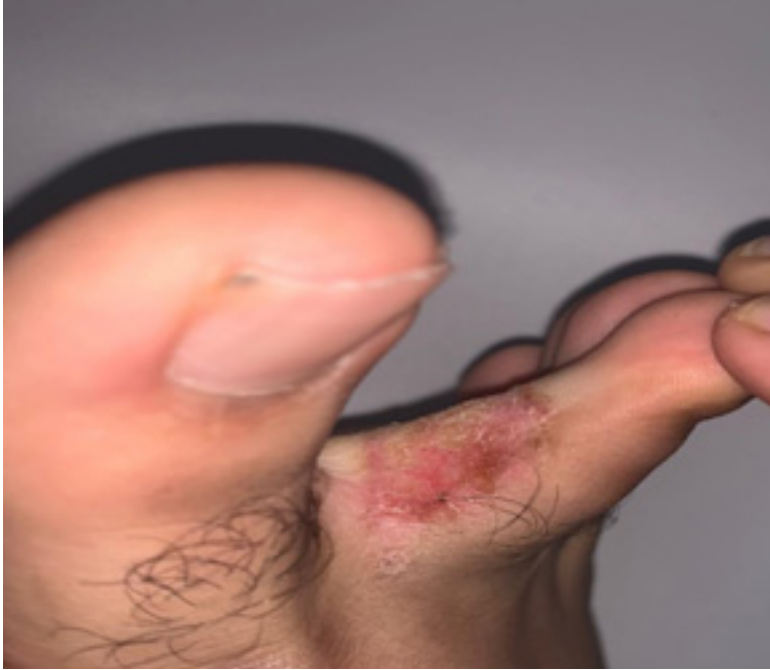Material and Methods

The task of history taking is not only complex but also depends on the patient's literacy (for example one patient was confused with a simple benign skin tag and on the other hand a mother would like to confirm a diagnosis for Molluscum contagiosum). Some patients give a very thorough and detailed history, while others require more probing in order to reach a probable diagnosis.

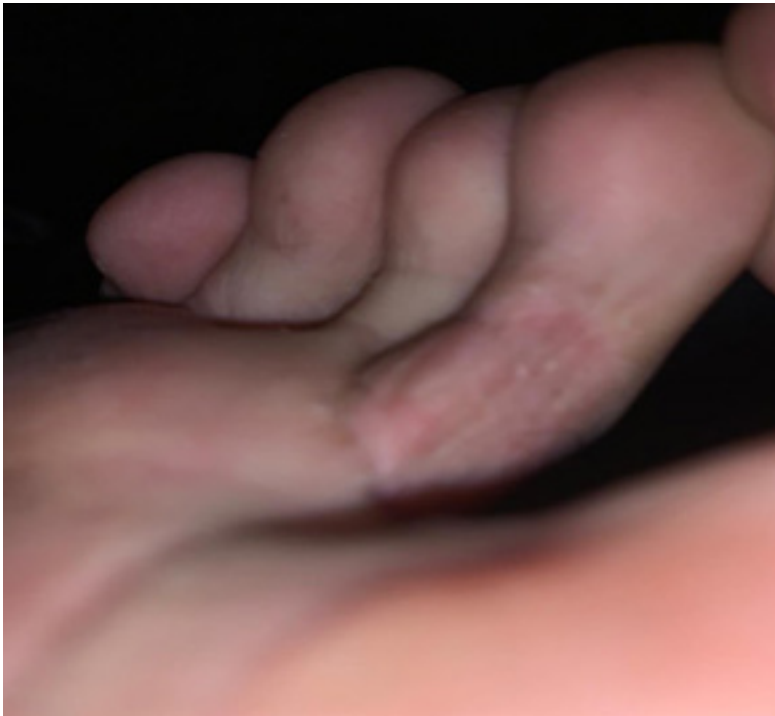I gathered a few common telephone cases (fungal, atopic, squamous vs basal CC and melanomas) to discuss during presentation. My plan is to use tool of consensus to select safe decision making in managing these concerned patients appropriately and timely (emergency skin rashes including infectious diseases related are excluded in this discussion).

Case 1

A 20 year old man called regarding dry, cracky and mildly itchy lesion on the right 2nd toe for the past 6 weeks. He plays sports regularly but due to Covid-19, he is not going out often and not using socks/trainers as he used to while playing sports. He is worried that he might have fungal infection. PMH: eczema in childhood. Pictures presented with consent:

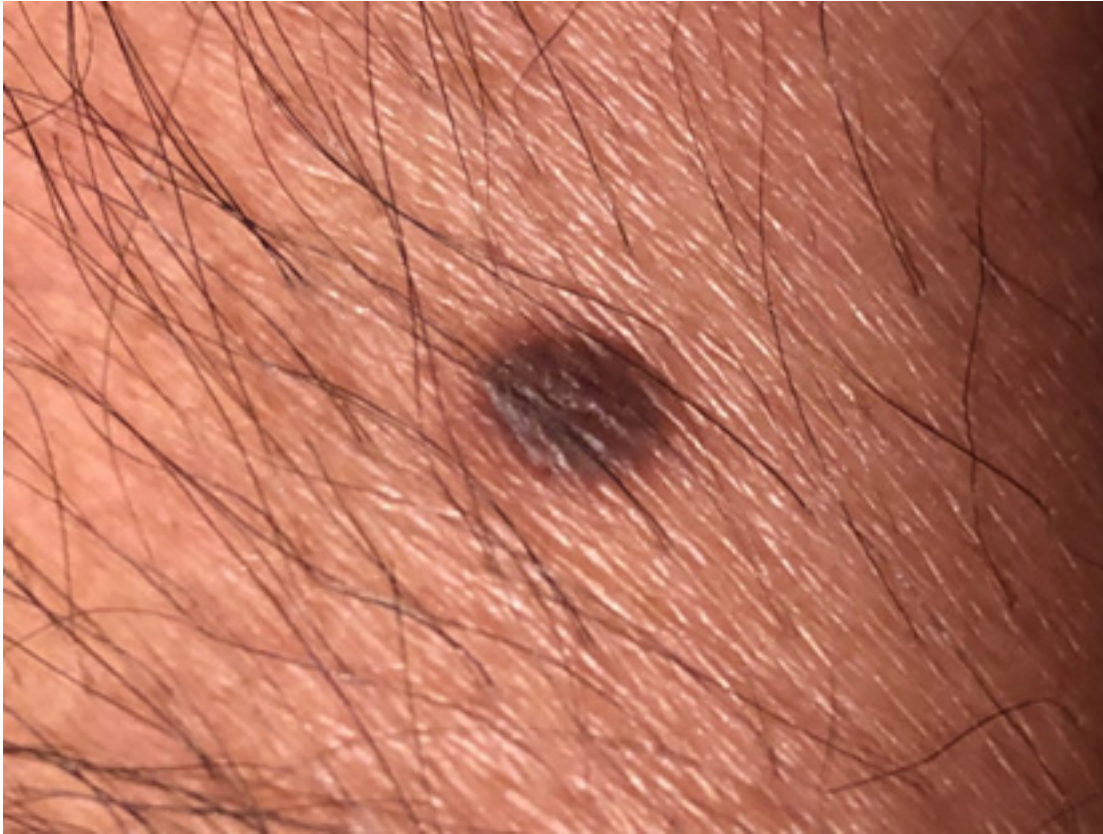
**Before treatment**

He was treated with Hydrocortisone 1% over the counter via telephone for eczema and 10 days later his lesion improved (picture attached). Eczema most often starts in infancy and affects two of ten children; it is also highly prevalent in adults (1).

**After treatment**

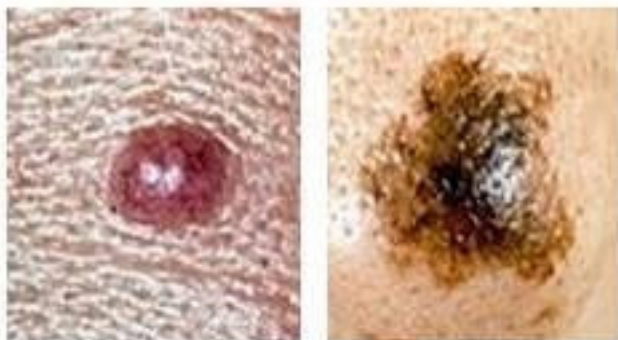Case 2

A 45 year old gentleman concerned about a mole on his leg since childhood, but recently got bigger, raised and itchy. On asking further he mentioned that the mole is black colour and around a pea size. He is not known to have any family history of Melanoma but he was concerned and would like to get it checked. PMH; fit and healthy. He was booked in office appointment two days later from that day. His lesion was measured 6mm but due to recent increase in size, raised and itchy he was referred to Dermatology on semi-urgent basis.



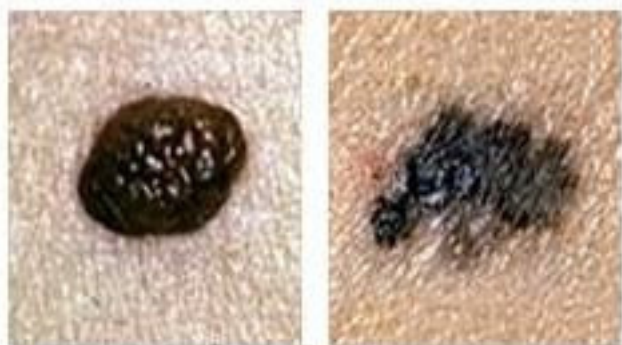Remember the ABCDE rule while taking history and in-office evaluation: **A**symmetry (one half of the mole doesn't match the other), **B**order irregularity, **C**olour that is not uniform, **D**iameter greater than 6 mm (about the size of a pencil eraser), and **E**volving size, shape or colour.

Asymmetry



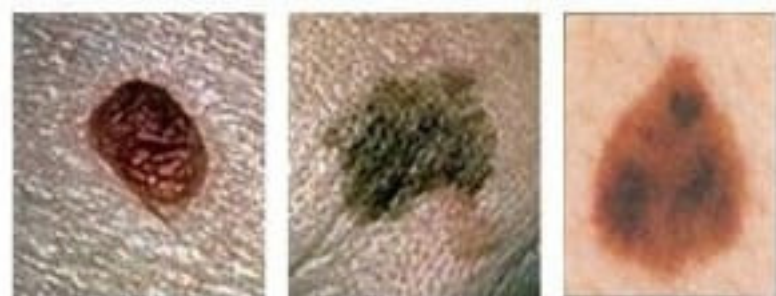Normal Mole –

Abnormal Mole

Borders

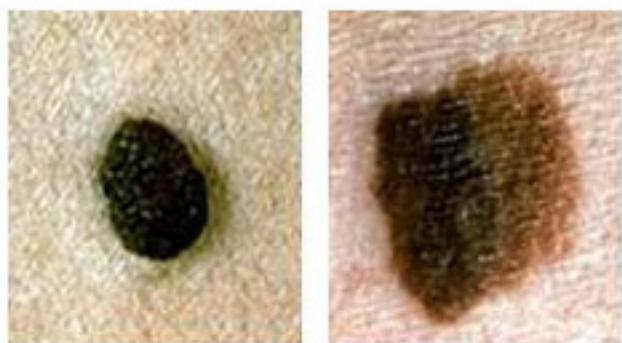Normal Mole –

Abnormal Mole

Colours

Normal Mole –

Abnormal Moles

Diameter

Normal Mole –

Abnormal Mole

Evolving

If you notice any CHANGE in size, shape or elevation of a mole, or experience any new symptom such as bleeding, itching or crusting, consider referral.

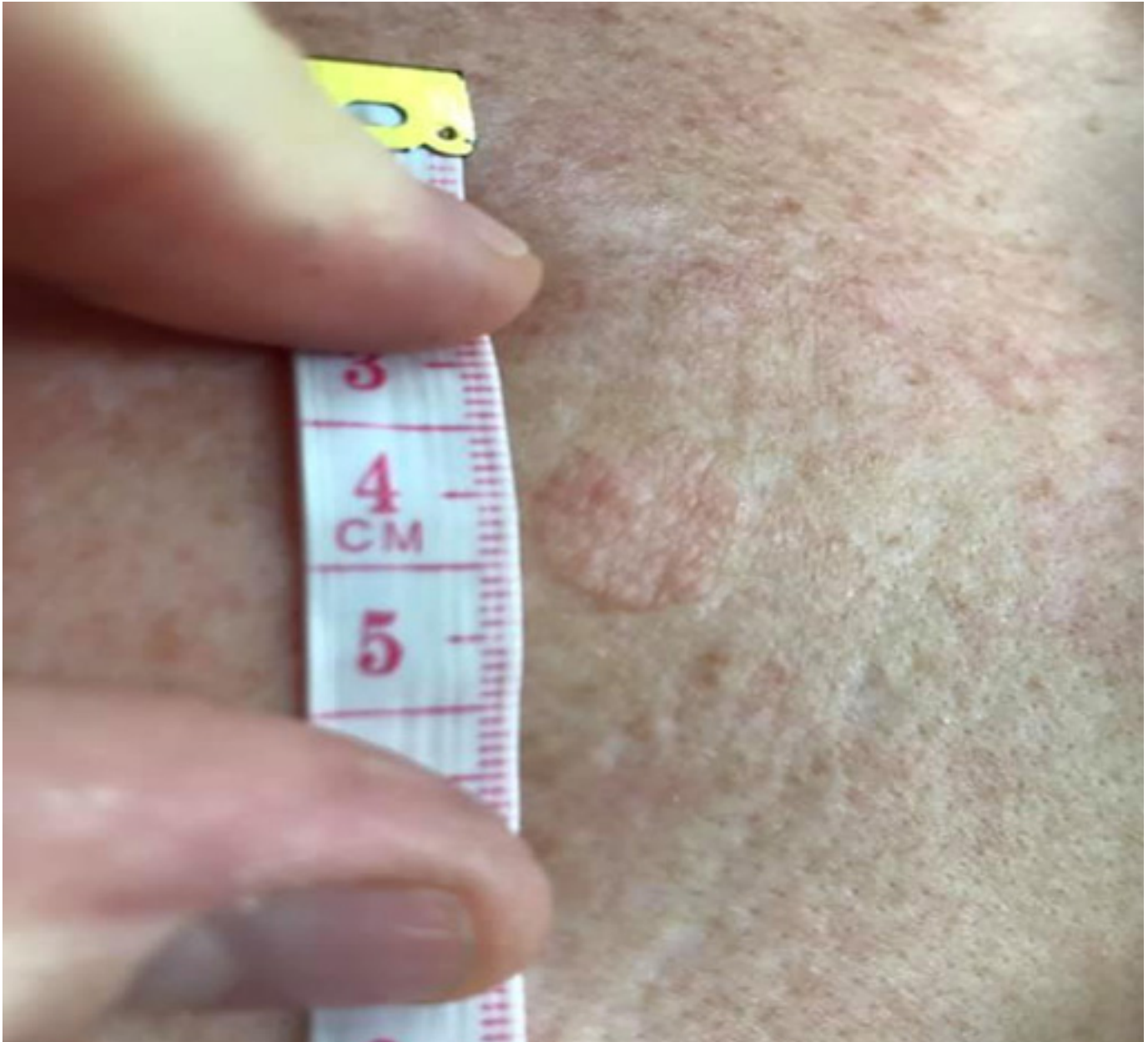Criteria for Referral — Primary care clinicians who identify a skin lesion that is not clearly benign should have a relatively low threshold for referral to a dermatologist for dermoscopic examination and evaluation for biopsy, if indicated. Guidelines published in 2010 by the British Association of Dermatologists suggest the following indications for referral [2]:

- A new mole appearing after the onset of puberty that is changing in shape, colour, or size
- A longstanding mole that is changing in shape, colour, or size
- Any mole that has three or more colours or has lost its symmetry
- A mole that is itching or bleeding
- Any new persistent skin lesion, especially if growing, pigmented, or vascular in appearance, and if the diagnosis is not clear
- A new pigmented line in a nail, especially where there is associated damage to the nail
- A lesion growing under a nail

His mole was excised and biopsy results returned as benign Lentiginous naevus.

Case 3

A 57 year old female called me for lesion on her chest for past 3 months, since exposure to sun recently it has become more prominent and itchy causing her concern to ask me for assessment face to face. She explained it as a red raised skin bump of around less than 5mm in size. She has strong family history of Squamous cell carcinoma otherwise fit and well. She was booked for next day face to face in-office appointment.

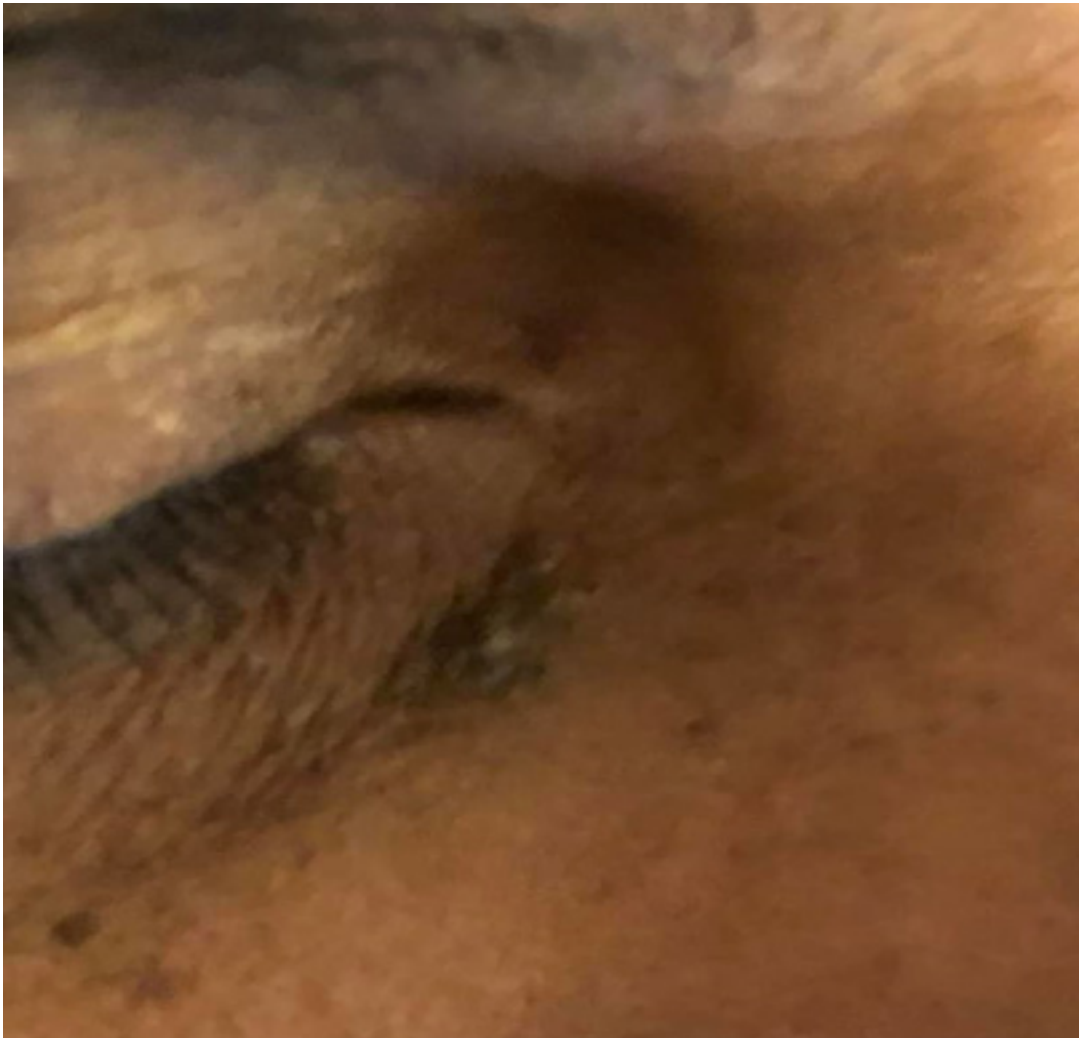

She was on the spot given liquid nitrogen therapy for possible Actinic Keratosis (AK) and prescribed 16 weeks treatment of Imiquimod 5% and referred to Dermatology on routine.

AKs are a concern because the majority of cutaneous SCCs arise from pre-existing AKs, and AKs that will progress to SCC cannot be distinguished from AKs that will spontaneously resolve or persist [3,4]. Because of these factors, most clinicians routinely treat AKs [5].

Case 4

A 50 year old asian man called for skin lesion around the nose beneath lower eye lid corner for several months, increased in size and more raised during last 6 months when he was transferred to Africa from Europe. Black in colour, never bleeds, itches or discharges. No family history of skin cancers. Patient is concerned about cancers. He was seen in the clinic two days later and referred to Dermatology on routine.



The lesion was diagnosed as seborrheic keratosis based on the clinical appearance of “stuck on,” warty, well-circumscribed (often scaly hyperpigmented lesions located most commonly on the trunk, face, and upper extremities). Close inspection with a hand lens often will demonstrate the presence of horn cysts or dark keratin plugs. Examination with a dermatoscope shows multiple milium cysts, comedo-like openings, and fissures and ridges forming a cerebriform pattern (6). It can left without treatment if small and not bothersome to patient. Commonly treated with cryotherapy or tri-chloroacetic acid peel.

Sometimes, seborrheic keratosis may resemble basal cell carcinoma, squamous cell carcinoma or melanoma. BCC and SCC are slow growing tumours and more common in whites than blacks or Asians. Hence referral on routine would be safe option when not sure and confused with seborrheic vs BCC vs SCC. But if suspected melanoma, then referral 2 week route would be safest option.

Results

A probable diagnosis may be acceptable with simple cases like dermatitis but can turn out to be disastrous in ruling out cancer. I have developed a safest approach to deal with such difficult cases, which is good history taking, efficient use of time and resources to see these patients safely and plan management accordingly.

Discussion

Using efficient history taking with proper planning, we can reach safe management plan during this Covid-19 virtual care and avoid any risk or harm to patients with concerns of skin cancer or skin conditions becoming worse.

References

1. Weidinger S, Novak N. Atopic dermatitis. *Lancet* 2016; 387:1109.
2. Marsden JR, Newton-Bishop JA, Burrows L, et al. Revised U.K. guidelines for the management of cutaneous melanoma 2010. *Br J Dermatol* 2010; 163:238.
3. Criscione VD, Weinstock MA, Naylor MF, et al. Actinic keratoses: Natural history and risk of malignant transformation in the Veterans Affairs Topical Tretinoin Chemoprevention Trial. *Cancer* 2009; 115:2523.
4. Marks R, Rennie G, Selwood TS. Malignant transformation of solar keratoses to squamous cell carcinoma. *Lancet* 1988; 1:795.
5. Ceilley RI, Jorizzo JL. Current issues in the management of actinic keratosis. *J Am Acad Dermatol* 2013; 68:S28.
6. Braun RP, Rabinovitz HS, Krischer J, et al. Dermoscopy of pigmented seborrheic keratosis: a morphological study. *Arch Dermatol* 2002; 138:1556.